

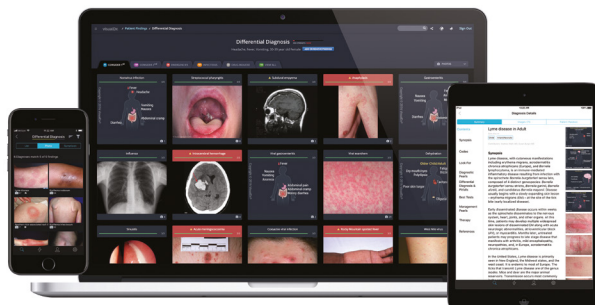
The Best Dermatology Images You Will Ever See

VisualDx® for Dermatology

VisualDx systematically catalogs the best dermatologic images in the world and using intelligent search to deliver diagnostic images and therapeutic knowledge at the point of care. Thousands of dermatologists use our images for patient education and to ease patient concerns. We help to solve the most challenging of diagnoses, thanks to our focus on representing the variation of disease presentation.

The Value of VisualDx for Dermatologists:

- Engage patients by sharing information and images.
- Instantly print patient handouts.
- Diagnose medication adverse events and drug-induced diseases.
- Diagnose disease variants and the most difficult cases.



Learn more at tools.ovid.com/visualdx.

VisualDX Quick Facts:

- In a random, blind study, VisualDx improved diagnostic accuracy **more than 120%**.
- **97%** of physicians believe using VisualDx improved patient care.
- Clinicians **save up to 26 minutes** per day when using VisualDx.
- **Over 3,000 Diagnoses**.
- **41,000+ Images** of disease or clinical guidance on therapy, management, pitfalls, and more.

A 64-year-old Caucasian male with past medical history of hypertension and hyperlipidemia but no history of allergies presented to dermatology clinic complaining of bilateral periorbital erythema for several weeks. Initially, it appeared like allergic versus contact dermatitis, and we extensively explored environmental and chemical contacts with which the patient may have been exposed. The only likely culprit we could surmise was the nickel scraping from the frequent lottery tickets the patient would scratch. When the likelihood of contact dermatitis was waning, I plugged the skin findings into the “Differential Builder” on VisualDx. One of the diagnoses offered was Pityriasis Rubra Pilaris (PRP).

At that point, the light bulb in my head illuminated! The patient had exactly that – the lesions were not actually erythematous but “orange-red” plaques that began on the face and “expanded to involve most of the body,” with “islands of normal skin.” We obtained a punch biopsy from one of his plaques, which confirmed my clinical suspicion (with help from VisualDx, of course!).

J.B. MD, Dermatology Resident

Key Features:



Powerful Differential Builder



Smart Search for Chief Complaints, Diagnoses, and Drug Reactions



Expert Content



Mobile Access



World's Largest Medical Image Library



Trademarked Sympticon Visualization Technology



Patient Engagement and Handouts



Earn CME

Learn more at tools.ovid.com/visualdx.